



Staining Pattern of Mucin Histochemical Stain Combined Alcian Blue-Periodic Acid Schiff Reaction of Thyroid Lesion in Shendi Town, Sudan

Zakia Salah Taha Mohammed Osma¹, Zeinab Ali Mohamed¹, Bishoy Faiz Malad Dawud¹, Tibyan Abdalmajed Altaher² and Ghanem Mohammed Mahjaf^{3*}

¹Department of Histopathology and Cytology, Faculty of Medical Laboratory Science, Shendi University, Sudan

²Department of Clinical Chemistry, Faculty of Medical Laboratory Sciences, Shendi University, Shendi, Sudan

³Department of Medical Microbiology, Faculty of Medical Laboratory Sciences, Shendi University, Shendi, Sudan

*Corresponding Author: Ghanem Mohammed Mahjaf, Department of Medical Microbiology, Faculty of Medical Laboratory Sciences, Shendi University, Shendi, Sudan.

Submitted: 30 Sept 2024

Accepted: 02 Oct 2024

Published: 14 Oct 2024

Citation: Ghanem Mohammed Mahjaf*, et al (2024) Staining Pattern of Mucin Histochemical Stain Combined Alcian Blue-Periodic Acid Schiff Reaction of Thyroid Lesion in Shendi Town, Sudan, J of Cancer & Oncology, Research Article. 2(3): 01-04.

Abstract

Background: Thyroid disease can increase daily due to their lifestyle. Worldwide, all populations are impacted by the prevalent illnesses hypothyroidism and hyperthyroidism, which can have disastrous health effects.

Objective: To study the staining pattern of mucin histochemical stain combined with alcian blue periodic acid schiff reaction of thyroid lesion in Shendi town, Sudan.

Methodology: A descriptive retrospective cross-sectional study conducted in Sudan, River Nile State, Shendi at El-Mak Nimer University Hospital, from December 2022 to February 2024, using alcian blue periodic acid schiff reaction of thyroid lesion.

Results: In our study, we found that females represent 92% of the population, and 8.0 % are males; the most common diagnosis is multinodular goiter, which is 86.0% of the total population. A vital statistically significant difference (P value 0.003) exists between different thyroid disease and staining reactions; multinodular goiter represents 74.4% of the PAS reaction, and 100% of malignant cases show Alcain blue-PAS reaction.

Conclusion: Strong correlation between staining reaction using combined Alcain blue-PAS technique in differentiation between benign and malignant conditions in thyroid lesions.

Keywords: Thyroid Lesion, Histochemical Stain, Alcian Blue, Periodic Acid Schiff

Introduction

Thyroid lesions are commonly encountered in clinical practice. From a clinical standpoint, the possibility of neoplastic disease is of significant concern in individuals who suffer from thyroid enlargement. Although tumors of the thyroid account for only 1% of the overall human cancer burden, they represent the most common malignancies of the endocrine system and pose a significant challenge to pathologists, surgeons, and oncologists [1]. Although the histopathological examination is the acknowledged gold standard in diagnosing thyroid lesions, controversies and pitfalls exist. It is known that the luminal surface of thyroid follicular tumor cells is covered by a glycoproteinaceous material that reacts positively with mucin

stains, like Alcian blue [2]. The thyroid gland is a butterfly-shaped organ located anteriorly to the trachea at the level of the second and third tracheal rings. It consists of two lobes connected by the isthmus in the midline; the weight of the thyroid of the average non-goitrous adult is 6–20 g, depending on the body size and iodine supply [3]. The thyroid gland contains many follicular cells that store the thyroid hormones within the thyroglobulin molecule until the body needs them. The thyroid hormones, often called the major metabolic hormones, affect virtually every cell in the body synthesis [4]. The thyroid is separated into lobules under the microscope; each lobule comprises 20–40 spherical follicles that range widely in size, from 45 to 250 μ m in diameter. In the newborn, follicles are small and grow slowly; each is lined

by a single cuboidal layer of epithelium (9–13 mm) with a thin basement membrane filled with an acidophilic colloid core [5]. Thyroid is a disease that can increase daily due to their lifestyle [6]. Worldwide, all populations are impacted by the prevalent illnesses hypothyroidism and hyperthyroidism, which can have disastrous health effects. A significant factor influencing the risk of thyroid illness is iodine nutrition; however, other variables include age, smoking status, genetic predisposition, ethnicity, endocrine disruptors, and the development of new treatments, including immune checkpoint inhibitors, also influence thyroid disease epidemiology [7]. The prevalence of thyroid disorders in Khartoum state, and to relate them with gender and age, was hyperthyroidism, and the rest, 1%, were hypothyroidism [8]. The epidemiology of goiter in Elfigaiga, River Nile State, Sudan, was 11.9%; the clinical assessment was done for both sexes at different age groups, and it was found that goiter was more frequent among females (85%); furthermore, it is mainly distributed within the age group 31-40 years (30%) [9]. The minority of human thyroid follicles that contain acid mucin are often grouped in the C-cell area of the gland and are lined by abundant C cells [10]. Pathologists try to seek the answers in the immunohistochemical markers. However, superficial histochemical stains can sometimes help the pathologist arrive at a diagnosis without the immunohistochemical stain, which is undoubtedly a costly affair [11]. The histopathological findings showed that hematoxylin-eosin can stain gray-bluish myxoid material so that a special stain can differentiate between myxoid material. Simplicity and cost-effectiveness are essential targets in our research for diagnosing thyroid pathology.

Methodology

This is a descriptive retrospective cross-sectional study aimed at studying the staining pattern of mucin histochemical stain combined with alcian blue periodic acid Schiff reaction of thyroid lesion in Shendi Town, River Nile State, Sudan, from December 2022 to February 2024. Fifty samples of tissue blocks of thyroid tissue were obtained from the hospital archive. The samples were transferred to the histopathology and cytology lab at Shendi University, where they were processed and examined.

Sample Collection and Processing

The selected tissues were sliced in the histopathology laboratory at El-Mak Nimer Hospital of Shendi, fixed in 10% formalin, and prepared into several paraffin-embedded tissue blocks. Fifty blocks were randomly selected from each block, and 50 sections of 3-5 μ m-thickness were cut using a rotary microtome.

Combine Alcian Blue-PAS

Deparaffinize the slide in the xylene for 6 minutes, hydrate the tissue section by passing through decreasing concentrations of alcohol baths (100%, 90%, 80%, 70%) and water for 2 minutes for each, stained with Alcian blue for 30 minutes, wash, Place the sections in periodic acid solution (1%) for 10 minutes, rinse

distilled water. Treatment with Schiff's reagent: Cover with Schiff's reagent for 20 minutes, wash in distilled water, and Rinse in tap water for 10 minutes. Cover with hematoxylin for 5 minutes, bluing in running tap water; Dehydrate in ascending concentration of alcohols. Clearing slides in xylene. Mount in Dibutylphthalate Polystyrene Xylene (DPX). Observe under a microscope [12].

Quality Control

Quality control was performed at each step and procedure during this study to ensure reliable performance and correct reporting of results. Colon tissue slides were used during staining as a positive control.

Data Analysis

After examination of the sections, the laboratory investigation results and the demographic data from the patient's records were processed using the Statistical Packages for Social Sciences (SPSS) computer program. Frequency, mean, and chi-square test values were calculated at <0.05 and considered statistically significant.

Results

Fifty archived paraffin-embedded tissue blocks from patients previously diagnosed with different histopathological thyroid diseases at El-Mak Nimer University Hospital at River Nile State were enrolled in this comprehensive study; 92% were females, and 8.0% were males. The staining reactions revealed that 70% of cases were positive for the PAS reaction, and 30% were positive for combined Alcian blue-PAS. The patient's age was categorized into three groups: 10- 30, 24.0%, 31- 60, 66.0%, more than 60, and 10.0% (Table 1). The most common diagnosis is multinodular goiter, with 86.0% of the total population (Table 2). The statistical solid significance P value of 0.003 between different thyroid diseases and staining reactions: multinodular goiter represents 74.4% of PAS reactions, and (100%) of malignant cases show Alcain blue PAS reactions (Table 3).

Table 1: The Frequency of Sample Among the Study Population

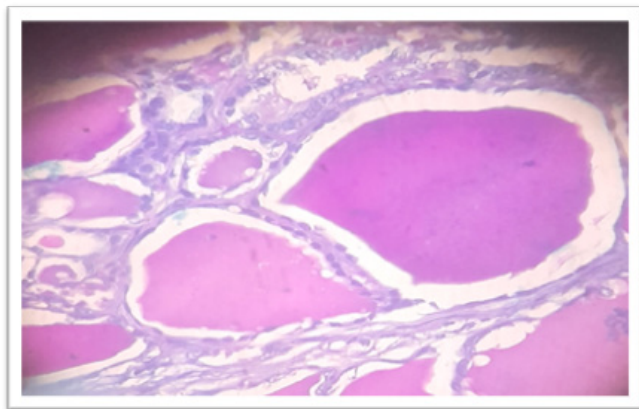
Age Group	Frequency	Percentage %
10-30 Years	12	24.0
31-60 Years	33	66.0
More than 60 Years	5	10.0
Total	50	100%

Table 2: The Frequency of Diagnosis Among the Study Group

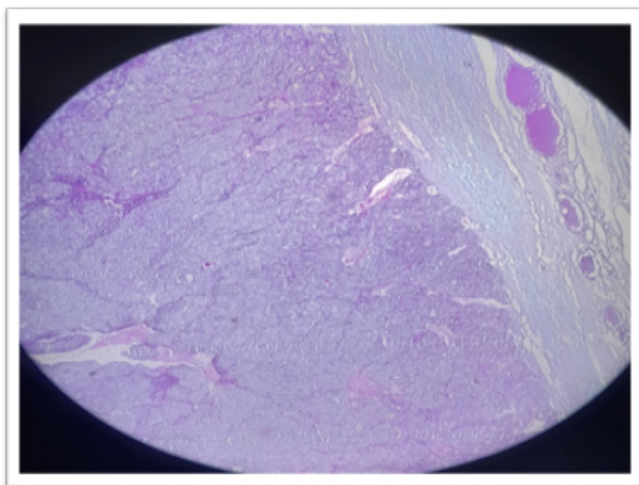
Diagnosis	Frequency	Percentage %
Multinodular goiter	43	86.0
Hashimoto	3	6.0
Malignant	4	8.0
Total	50	100%

Table 3: The Correlation between Diagnosis and Staining Reaction Among the Study Group

Diagnosis	Staining reaction		P.value
	PAS	AB-PAS	
Multi nodular goiter	74.4%	25.6%	0.003
Hashimoto	100%	0%	
Malignant	0%	100%	



Microphotograph 1: Multinodular Goiter Showing Alcian Blue- Periodic Acid Schiff (AB-PAS) Stain Showing PAS Positive



Microphotograph 2: Follicular Carcinoma Showing Alcian Blue- Periodic Acid Schiff (AB-PAS) Stain Showing AB (blue) Some PAS Positive

Discussion

Goiter has been recognized in Sudan as a public health problem since the 1950's. Nationwide surveys on Google were launched, and various approaches in the quest for a solution to the problem were applied. Still, the number of goitrous individuals continues to grow each year. This article highlights and reiterates the staining pattern of mucin histochemical stain and the blue-periodic acid Schiff reaction of a thyroid lesion in Shendi Town, Sudan. The current study has shown that, in terms of the frequency of the gender distribution, females were more affected

(92%) with thyroid disorders than males (8%). This finding was in agreement with Amin A. Elzaki and Hamid Osman in 2012, who found goiter was more prevalent among females (80.8%) as compared to males (11.2%) with a female: male ratio of 8:1 [13].

Our study shows a vital statistically significant difference (P value 0.003) between different histopathological disorders and staining reactions. Using the combined AB-PAS reaction, multinodular goiter represents 74.4 percent of the PAS reaction, and 100% of the malignant cases show the Alcain blue-PAS reaction. This finding was in disagreement with a study done by Seetu Palo and Dayananda S. Biligi in 2015, that said the diagnostic ability of Alcain blue (pH 2.5) staining in distinguishing between hyperplastic, benign, and malignant thyroid lesions was statistically not significant ($p > 0.01$) [11].

The discrepancy might result from the staining technique of using alcian blue alone without combination with PAS. In our study, the patient's age was categorized into three groups; the most common age group ranged from 31 to 60 (66.0%). This finding disagreed with a study by Khalid Eltohami Medani in 2020, who reported that 45-64 years (13.4%). That may be due to sample size or the categorization method of age group [8]. Furthermore, there may be an essential rule of genetic characteristics in thyroid conditions pathogenesis, as inferred from the study of Strieder et al. [14].

Conclusion

Our study demonstrated that females were more affected by thyroid disorders than males (92%, 8%). Middle and older age are more affected by thyroid disease (66.0%). A strong association exists between staining reactions using the combined Alcain blue-PAS technique in differentiation between benign and malignant conditions in thyroid lesions.

Consent

The patient's written consent has been collected.

Ethical Approval

The study was approved by the Department of Histopathology and Cytology in Medical Laboratory Sciences at Shendi University, the study was matched to the ethical review committee board. Sample collection was done after signing a written agreement with the participants. Permission for this study was obtained from the local authorities in the area. The aims and the benefits of this study were explained with the assurance of confidentiality. All protocols in this study were done according to the Declaration of Helsinki (1964).

Acknowledgment

The authors appreciate the ethical review committee, and thanks are also due to the Department of Histopathology & cytology at the Faculty of Medical Laboratory Sciences providing the research facilities for this study.

Sources of Funding

There was no specific grant for this research from any funding organization in the public, private, or nonprofit sectors.

Conflict of Interest

The authors have declared that no competing interests exist.

References

1. RA D (2004) Tumors of the thyroid and parathyroid. World Health Organization classification of tumors: pathology & genetics. Tumors of Endocrine Organs 2004: 49-134.
2. Rosai J (2011) Rosai and Ackerman's surgical pathology e-book. Elsevier Health Sciences https://books.google.co.in/books/about/Rosai_and_Ackerman_s_Surgical_Pathology.html?id=1CKX7aGBbUsC&redir_esc=y.
3. Guidoccio F, Aghakhanyan G, Grosso M (2019) Hybrid Imaging and Radionuclide Therapy for Thyroid Disorders. Nuclear Medicine Textbook: Methodology and Clinical Applications 2019: 707-747.
4. Kirsten D (2000) The thyroid gland: physiology and pathophysiology. Neonatal network: NN 19: 11-26.
5. Benvenga S, Tuccari G, Ieni A, Vita R (2018) Thyroid gland: anatomy and physiology. Encyclopedia of Endocrine Diseases 4: 382-390.
6. Dharmarajan K, Balasree K, Arunachalam AS, Abirmai K (2020) Thyroid disease classification using decision tree and SVM. Indian Journal of Public Health Research & Development 11: 224-229.
7. Taylor PN, Albrecht D, Scholz A, Gutierrez-Buey G, Lazarus JH, et al. (2018) Global epidemiology of hyperthyroidism and hypothyroidism. Nature Reviews Endocrinology 14: 301-316.
8. Medani KE (2020) Prevalence of Thyroid Disorders and Reference Range of Thyroid Hormones in Khartoum State, Sudan. Journal of Research in Medical and Dental Science 8: 158-161.
9. Elamin A, Mahmoud M (2016) Epidemiology of goiter in Elfigaiga, River Nile state, Sudan. Int J Community Med Public Heal 3: 977-981.
10. Harach HR (1991) Thyroglobulin in human thyroid follicles with acid mucin. The Journal of Pathology 164: 261-263.
11. Palo S, Biligi DS (2015) Role of Alcian blue (pH 2.5) histochemical stain in diagnostic thyroid pathology: how far is it helpful?. International Journal of Research in Medical Sciences 3: 3766.
12. Bancroft JD, Gamble M (2008) Theory and practice of histological techniques. Elsevier Health Sciences <https://knustmeltsa.wordpress.com/wp-content/uploads/2020/08/bancrofts-theory-and-practice-of-histological-techniques-7th-edition-0702042269autosaved1.pdf>.
13. Elzaki AA, Osman H (2012) Goitre by Using Scintigraphy and Biopsy in Sudan. Afro-Egyptian Journal of Infectious and Endemic Diseases 2: 1-6.
14. Strieder TG, Prummel MF, Tijssen JG, Endert E, Wiersinga WM (2003) Risk factors for and prevalence of thyroid disorders in a cross-sectional study among healthy female relatives of patients with autoimmune thyroid disease. Clinical endocrinology 59: 396-401.

Copyright: ©2024 Mahjaf GM, et al. This is an open-access article distributed under the terms of the Creative Commons Attribution License, which permits unrestricted use, distribution, and reproduction in any medium, provided the original author and source are credited.