



# Verruciform Xanthoma with Signs of Acantholysis in the Context of Papash Syndrome: Case Presentation and A Literature Review

Francisco Javier Torres Gómez<sup>1\*</sup>, Mora Díaz R<sup>1</sup>, Montaña-Ramírez AM<sup>1</sup>, López-Prieto A<sup>1</sup> and Álvarez-Muñoz A Rendón-García R<sup>1</sup>

Pathology Service, Virgen Macarena University Hospital, Seville, Spain

\*Corresponding Author: Francisco Javier Torres Gómez, Pathology service. Virgen Macarena University Hospital. Seville. Spain. Phone No: 34+629344869.

Submitted: 09 July 2024 Accepted: 12 July 2024 Published: 15 July 2024

**Citation:** Francisco Javier Torres Gómez, Mora Díaz R, Montaña-Ramírez AM, López-Prieto A and Álvarez-Muñoz A Rendón-García R (2024). Verruciform Xanthoma with Signs of Acantholysis in the Context of Papash Syndrome: Case Presentation and A Literature Review. *J of Clin Case Stu, Reviews & Reports* 2(7), 1-3.

## Abstract

Verruciform xanthoma is an exophytic papillomatous lesion with benign clinical behavior whose main anatomical location is the oral cavity, although cases have been described with different frequencies at the cutaneous and mucosal level such as the vulva, anus and scrotum. Its most frequent clinical presentation occurs in isolation, although cases of more than one synchronous or metachronous lesion have been reported. The warty morphology and superficial location allow the presence of the lesion to be detected early, although the diagnosis requires the relevant histological study in which the subepithelial presence of characteristic foamy histiocytes is demonstrated, postulating an inflammatory etiology as the main cause, a hypothesis that would support the reactive nature of injury. However, the description of the PASH syndrome, whose spectrum includes hidradenitis suppurativa, pyoderma gangrenosum, acne and pyogenic arthritis in a condition characterized by injury and destruction of the hair follicle, does not include verruciform xanthoma as a corporate lesion.

Our patient's successive outbreaks of anal suppurative hidradenitis suggest the inclusion of this peculiar lesion in the morbid spectrum of the cited syndrome.

**Keywords:** Verruciform; Xanthoma; PASH syndrome; Anal; Mucocutaneous.

## Introduction

Verruciform xanthoma is a benign exophytic papillomatous lesion that is usually found in the oral cavity, although on rare occasions it can be found in multiple other locations, such as the vulva, anus or scrotum [1]. Generally, they tend to be single lesions, in the form of orange-colored plaques or papules, which can appear at any age, although it is more common around the fifth decade of life [2]. Although the etiopathogenesis is unknown, multiple hypotheses have been postulated in relation to the etiology of the lesion, with chronic inflammation and repetitive trauma being the most probable causes, since verruciform xanthomas usually settle in areas exposed to mechanical friction [3]. According to its exophytic morphology, it is necessary to consider the differential diagnosis with sexually transmitted diseases (human papillomavirus, although a causal relationship has not been established and other inflammatory, hypertrophic or keratotic entities such as lichen sclerosus, Paget's disease or squamous cell carcinoma [4,5].

From the histological point of view, verruciform xanthoma is characterized by accumulations, at the level of the lamina propria, of histiocytes with vacuolated cytoplasm's loaded with lipids that show a clear shade with routine stains (hematoxylin-eo-

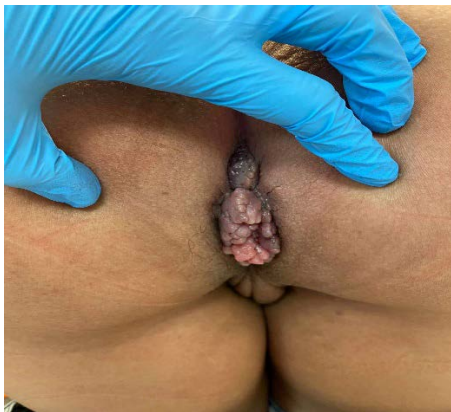sin). They are accompanied by a variable inflammatory cellular infiltrate, mainly lymphocytes, although the presence of eosinophils or plasma cells is not uncommon. The lesion is covered by a stratified, non-dysplastic, squamous epithelium, frequently hyperplastic with hyperkeratosis. Although without a defined etiology, it has been suggested that repetitive trauma may be the cause of the degeneration of keratinocytes and the accumulation of xanthic macrophages [6].

Treatment is symptomatic and pain control in frequently necessary but surgical excision is almost always the definitive treatment.

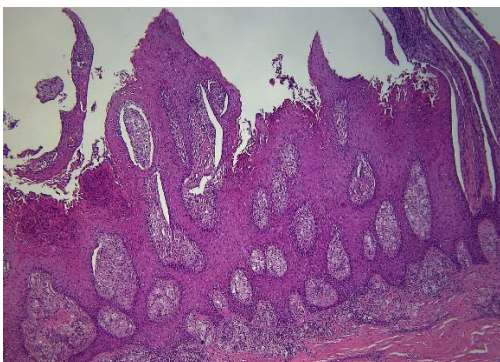
## Clinical Case

A 55-year-old male patient presented with an excrescent and pedunculated lesion measuring 2 cm in greatest dimension on the anal margin (Fig 1), of six months' duration. The clinical history includes multiple surgical interventions motivated by recurrent anal hidradenitis suppurativa associated with the formation of perianal fistulas. The history of multiple episodes of complicated acne and episodes of joint lesions followed by the Rheumatology service allows the syndromic condition to be framed in the context of a PASH syndrome. With the clinical judgment of

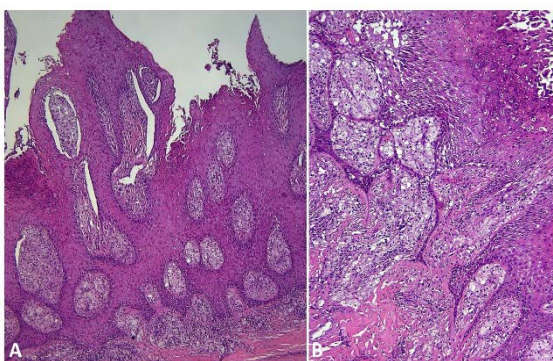
an exophytic lesion to be confirmed, surgical excision of the anal lesion was performed, which was sent to the Pathology service. Upon histological study, at the epidermal level, extensive areas of acantholysis are identified that lead to a subtotal thinning of the stratum spinosum, along with superficial neutrophilic aggregates. Furthermore, dermal papillae show abundant subepithelial xanthic macrophages (Fig 2-3). After carrying out immunohistochemical and molecular biology (HPV) techniques, viral etiology and negativity for PAS and S-100, as well as positivity for lipophilin (Fig 4), were ruled out.



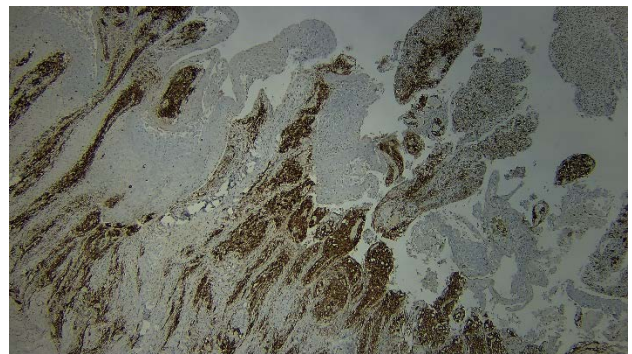
**Figure 1:** Anal verruciform xanthoma. Clinical image



**Figure 2:** Anal verruciform xanthoma. Histology. Verruciform Epithelial Hyperplasia Without Atypia. The Lesional Silhouette Is Reminiscent of Church Spires. In This Panoramic View, Histiocytic Collections Are Seen at The Level of The Superficial Lamina Propria. HE 100x.



**Figure 3:** Anal Verruciform Xanthoma. Histology. A Exophytic Morphology of the Lesion. HE 40x ,B: Subepithelial Xanthic Macrophage Aggregates. HE 100x.



**Figure 4:** Anal Verruciform Xanthoma. Histology. Immunohistochemical Staining for Lipophilin Shows Intense Positivity in Xanthic Cells. Lipophilin 200x.

### Discussion

Verruciform xanthoma is a benign tumor lesion first described in 1971 by Shafer [7]. It's slow and progressive growth and its warty morphology, together with its preferential location in oral and genital mucous membranes, require surgical excision that is not only therapeutic but also diagnostic, since its phenotypic resemblance to condyloma acuminata or other lesions associated with sexually transmitted infections is transcendent. A similar statement can be made when addressing lesions located at the skin level, although the differential diagnosis can be even more extensive since there are many entities that exhibit a similar morphology. It should not be surprising, therefore, that during the histological study, complementary tests are requested focused on ruling out the viral nature, as occurs with the determination of the presence of the human papillomavirus (HPV) as well as others such as cytomegalovirus (CMV) The latter scenario is more common in immunosuppressed patients, especially if clinical suspicion and, above all, microscopic findings so advise.

The pathological accumulation of histiocytes with a “foamy” phenotype also forces us to consider histological differential diagnoses with lesions characterized by stromal (or dermal, if applicable) colonization by clear cells with a macrophage appearance.

PAPASH syndrome is a rare entity that encompasses, together with hidradenitis suppurativa, the presence of acne, pyogenic arthritis and pyoderma gangrenosum [8]. Although no case of association between the appearance of verruciform xanthoma and PAPASH syndrome has been previously described in the literature, the pro-inflammatory environment could be considered as a facilitator for its development. Hidradenitis suppurativa is a chronic disease that affects the epithelium of hair follicles, characterized by follicular destruction and the appearance of fibrosis along with suppurative lesions causing a release of inflammatory mediators in the dermis that conclude in an abnormal activation of the innate immune system [9]. There could be a connection between the alteration of keratinization and activation of the autoinflammatory response with the macrophage accumulation of verruciform xanthoma.

In conclusion, we present a case of verruciform xanthoma with

an atypical location due to its presentation in the anal margin in the context of PAPASH syndrome associated with hidradenitis suppurativa, having not been previously described in the literature, so it may be a chance finding.

## References

1. May P Chan (2019) Verruciform and Condyloma-like Squamous Proliferations in the Anogenital Region. Arch Pathol Lab Med 143: 821-831.
2. Harshila Patel, Monika Wagner, Puneet Singhal, Smita Kothari (2013) Systematic review of the incidence and prevalence of genital warts. BMC Infect Dis 13: 39.
3. Lara Cumberland, Ali Dana, Brooke Resh, James Fitzpatrick, Gary Goldenberg (2010) Verruciform xanthoma in the setting of cutaneous trauma and chronic inflammation: report of a patient and a brief review of the literature. J Cutan Pathol 37: 895-900.
4. Lamaroon A, Vickers RA (1996) Characterization of verruciform xanthoma by in situ hybridization and immunohistochemistry. J Oral Pathol Med 25: 395-400.
5. Aldo Franco De Rose, Mattia Tosi, Guglielmo Mantica, Nataniele Piol, Carlo Toncini, et al. (2016) Verruciform xanthoma of the penis: A rare benign lesion that simulates carcinoma. Arch Ital Urol Androl 88: 284-285.
6. S K Mohsin, M W Lee, M B Amin, M H Stoler, E Eyzaguirre, et al. (1998) Cutaneous verruciform xanthoma: a report of five cases investigating the etiology and nature of xanthomatous cells. Am J Surg Pathol 22: 479-487.
7. W G Shafer (1971) Verruciform xanthoma. Oral Surg Oral Med Oral Pathol. 31: 784-789.
8. Simone Garcovich, Giovanni Genovese, Chiara Moltrasio, Dalma Malvaso, Angelo Valerio Marzano, et al. (2021) PASH, PAPASH, PsAPASH, and PASS: The autoinflammatory syndromes of hidradenitis suppurativa. Clin Dermatol 39: 240-247.
9. Ditte Marie Lindhardt Saunte, Gregor Borut Ernst Jemec (2017) Hidradenitis Suppurativa: Advances in Diagnosis and Treatment. JAMA 318: 2019-2032.

*Copyright: ©2024 Francisco Javier Torres Gómez. This is an open-access article distributed under the terms of the Creative Commons Attribution License, which permits unrestricted use, distribution, and reproduction in any medium, provided the original author and source are credited.*