

Closure of De functioning Colostomy: Causes, Types, Sites and Early Complications

Ashraf Abdulrazzaq Mohammed^{1*}, Zaid Mahmood Taher² and Samid Qais Mahmood³

¹Al-Salam Teaching Hospital / Nineveh Health Directorate Academic Affiliation: Iraqi Ministry of Health / Syndicate of Iraqi Doctors
Address: Mosul / Nineveh

²Tal'Afar General Hospital Academic Affiliation: Iraqi Ministry of Health Address: Mosul / Nineveh

³Al-Salam Teaching Hospital / Nineveh Health Directorate Academic Affiliation: Iraqi Ministry of Health / Syndicate of Iraqi Doctors
Address: Mosul / Nineveh

*Corresponding author: NAshraf Abdulrazzaq Mohammed, Al-Salam Teaching Hospital / Nineveh Health Directorate Academic Affiliation: Iraqi Ministry of Health / Syndicate of Iraqi Doctors Address: Mosul / Nineveh. IRAQI.

Submitted: 05 May 2023 Accepted: 07 May 2023 Published: 13 May 2023

Citation: Ashraf Abdulrazzaq Mohammed, Zaid Mahmood Taher and Samid Qais Mahmood (2023). Closure of De functioning Colostomy: Causes, Types, Sites and Early Complications, J of Surgery & Anesthesia 1(1), 01-07.

Abstract

Background: De functioning colostomy is a common operation, and is made for different reasons in emergency cases and in elective cases, it has different types which serve almost the same purpose; whether it is emergency or elective, it has possible complications that may range from simple complications which can be treated conservatively to severe complications which can be life threatening.

Aim: To recognize the association between the different types/sites of defunctioning colostomy and the possible post-closure complications considering the indication for which colostomy was made, to decrease hospitalization period & permit early return to normal life with least complications.

Patients and Method: Retrospective clinical case series study sustained in Mosul Teaching Center in the period from 2018 – 2020, with sample size 51 cases. Adult patients with temporary colostomy are included in the study. Permanent terminal colostomy, pediatrics is excluded.

History, examination, colonoscopy, barium enema and patient preparation before intervention are done. Results: A sample of 51 patients with temporary colostomy closed, complications happened in 37.26%, the most common complication was surgical site infection, the least complications site were found to be with Lt. side colostomies & with the loop type of colostomies. **Conclusion:** Closure of loop type of colostomy has least complications. The transverse colon site of colostomy has the best outcomes after closure. Good patient selection with proper timing & preparation are important factors for successful outcomes.

Keywords: Closure Colostomy, Defunctioning Colostomy, Temporary Colostomy, Complications of Colostomy Closure

Introduction

The colostomy is a surgical procedure that makes an opening in the large intestine out through the abdominal wall. Using this procedure, the colon is diverted through an incision in the abdominal wall to create a stoma. A stoma is the opening in the skin where a pouch for collecting feces is attached [1]. The first colostomy was successfully performed for trauma in 1795. However, until the World War II the colostomy became the cornerstone of therapy for injuries to the colon and rectum [2].

Hartmann's procedure was first described in the early 1920's by a French surgeon that named the procedure and was initially performed in patients with left colon neoplastic obstruction; the intention was to decrease mortality due to anastomotic leakage.

With time, its indication has been extended to benign disorders such as complicated diverticulitis, gunshot wound to the colon and complications after primary colonic anastomosis [3].

In adults, the main conditions which require colostomy formation are: Volvulus, diverticulitis, trauma, and malignancies occasionally, require stoma formation as part of their management, the major purposes for performing a stoma are to divert stool flow, protecting anastomotic site, bowel decompression, or a combination of these indications [4].

The colostomy type's fall in two categories either temporary (Loop, double barrel, Vent colostomy) or permanent (end colostomy) as shown in (Fig 1).

It has been suggested that the ideal diverting stoma meet several criteria such as it should provide complete fecal diversion, it should be so constructed as to permit easy closure as well as it should be complication free and finally from the outside it should be aesthetically acceptable and manageable for the patient [5].

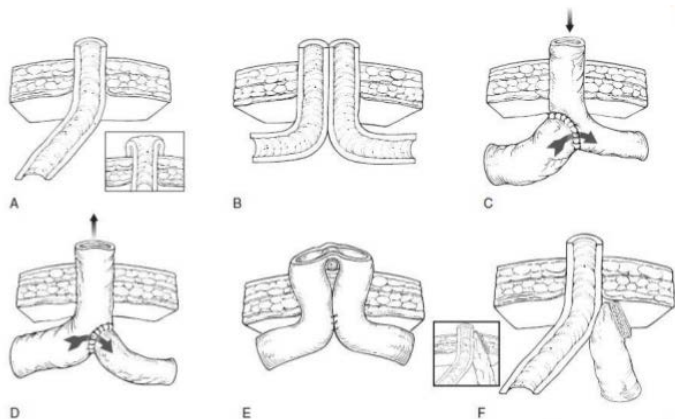


Figure 1: Types of colostomy

The traditional loop colostomy has difficulty in meeting some of these criteria. Many doubts have been voiced as to its ability to completely divert the fecal stream. In addition, the use of a supporting rod does not allow the early, easy application of the correct sized bag (Fig.2).

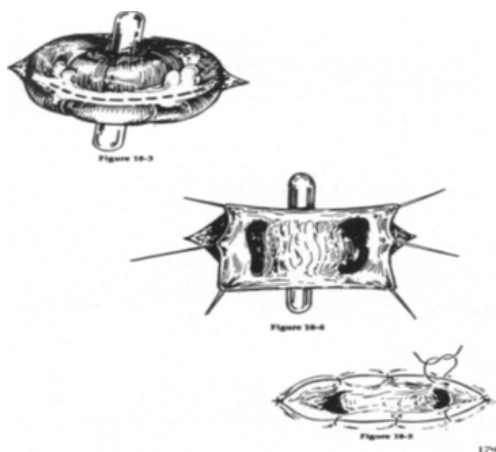


Figure 2: Temporary loop colostomy

The Ostomies can be performed at different sites on the bowel, examples are shown in (Fig.3).

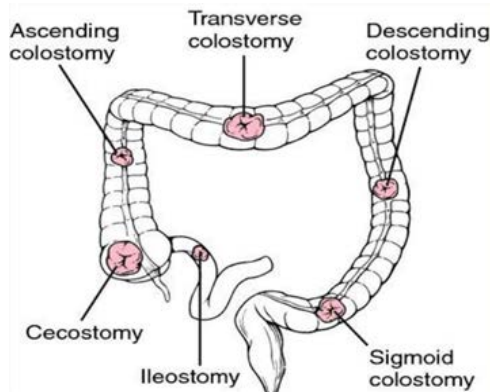


Figure 3: Sites of Ostomies

The optimal timing for the closure of the stoma has been reported to range from one month to three months of the initial operation. It has been reported that, if the repair is done earlier than four weeks the risk of anastomotic breakdown is high due to edema, inflammation, and collagenase activity at the site, while after three months the stoma becomes firmly adherent to the surrounding tissue due to fibrosis [4].

Several techniques of intestinal continuity restoration have been described over the past decades. Stomas are usually temporary but they may become permanent; this is owed to several and different factors, such as: age, distal (rectal) stump size and patient's comorbidities [3].

Gastrografin enema, sigmoidoscopy, or colonoscopy should be performed for the patients prior to closure to assess the patency of the distal segment.

Patients need to have mechanical preparation of the proximal and distal bowel with cessation of oral feeding the day before operation, orthograde lavage using solution orally administered (e.g.: polyethylene glycol) and irrigation of the distal loops prior to surgery; however, some say this may lead to electrolyte disturbance. All patients must have preoperative parenteral antibiotic treatment immediately prior to operation preferably a 3rd generation cephalosporin and metronidazole [6].

The operation entails taking down the stoma and performing a bowel anastomosis to re-establish the colon continuity (Fig.4).

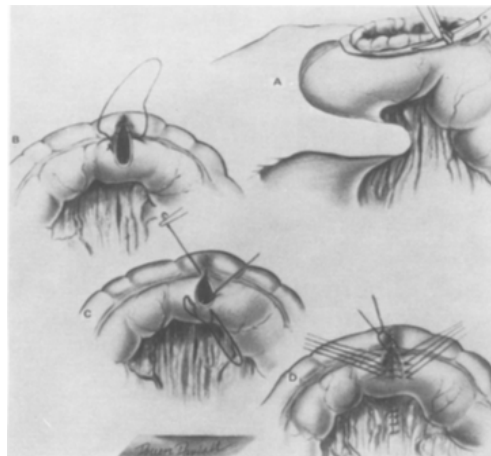


Figure 4: Simple loop closure: A: The stomal edge is trimmed. B: Connell suture is started at both ends with the first stitch placed wellbehind the corner and tied on the inside. C: Both sutures are brought to midpoint and tied. D: Lembert sutures are placed and the bowel is returned to abdomen.

Postoperatively, the patient remains in the hospital for two to three days with nothing by mouth. The closure of stomas has been reported to be associated with significant complications and even mortality and should not be considered as a minor procedure. The technique of colostomy closure has been reported to have an effect on the outcome of patients following stoma closure [1].

In the past, extraperitoneal stoma closure used to be commonly performed with the hope to contain the leak outside the peritone-

al cavity. However, recently intra-peritoneal closure of stoma is more commonly performed and allows proper identification of the anastomosis under vision.

Complications associated with colostomies are both early and late. The morbidity after colostomy closure varies widely; there are risk factors responsible for a high complication rate which may result from colostomy closure, e.g.: Very early reversal of the stoma, reversal of the stoma in a contaminated field. It was found that adequate preoperative bowel preparation, secondary suture of the wound and delaying of colostomy closure for 2-3 months after initial procedure may be beneficial in reducing the high morbidity [7]. Complications following closure of colostomy may include: Wound infection, dehiscence, anastomotic leak, ileus, post-operative bleeding (early/late), seroma and incisional hernia.

So, closure of colostomy requires high standards of surgical care as any anastomosis of the large intestine to avoid / minimize such complications [8].

Patient and Method

- Design: Retrospective clinical case series study
- Setting: Mosul Teaching Center
- Study period: 16. January.2018 – 20. August.2020
- Sample size: 51 cases
- Inclusion criteria: (Sampling technique): Adult patients with temporary colostomy
- Exclusion criteria: Permanent terminal colostomy, pediatrics.
- Intervention: History, examination, colonoscopy, barium enema and patient preparation

A study of 51 patients who have temporary colostomies of different types for various causes and indications who were operated in the Mosul Teaching Center for the temporary stoma creation & returned for stoma closure.

According to the surgeon preference & facility available, barium study was made for some of those patients before closure to verify the patency of the distal segment while other patients underwent sigmoidoscopy or colonoscopy for the distal segment. All the patients were admitted two days before the date of the co-

lostomy closure operation and they were kept on clear oral fluid diet and were given a purgative orally (polyethylene glycol) till they pass clear fluid bowel motion and repeated enema through the anus (and distal colostomy loop if applicable).

A dose of intravenous 3rd generation cephalosporin & metronidazole were given 30min. before operation. The time from the colostomy creation till its closure ranged from 4-12 weeks depending on the general condition of the patient, the associated injuries, the presence of complications after the initial surgery for the stoma creation and the surgeon preference. Most of the operations of the colostomy closure were done by the same surgeon who made those colostomies.

The surgical procedure was to dissect and release the stoma free from the surrounding skin and underlying tissue then to excise the edges of the bowel on the released stoma then end-end anastomosis outside the peritoneal cavity(in case of loop & double barrel colostomy) or intra-peritoneal anastomosis(in case of Hartmann colostomy), both in double layer suturing(1st layer by vicryl 2/0 continuous manner & 2nd layer by silk 3/0 interrupted manner) then putting the colon in a tension-free position, putting a corrugated drain, sometimes a subcutaneous drain too and the abdomen closed in layers.

Lord's dilatation was made for all patients before recovering from anesthesia. Postoperatively the patients were still on the same IV antibiotic and metronidazole but with higher doses, IV fluid, encouraged for early mobilization and chewing and kept fasting till the patient has positive bowel sounds which is considered the sign to start oral fluids. All the patients followed up during their stay and after discharge from the hospital till all drains and stitches were removed and no symptom/sign of infection or other complication is there (intra-peritoneal drain left for 5-7 days, subcutaneous drains left for 4-5 days).

Statistical Analysis: Fisher exact test, where p-value is significant if <5%

Results

Fifty-one patients underwent operations for closure of their different types of colostomy (Table.1).

Table 1: Types of Colostomies in this Study

Type of colostomy	Number of cases	Percentage
Loop colostomy	24	45.09%
Double Barrel colostomy	18	35.29 %
Hartmann colostomy	5	9.80%
Vent colostomy	4	7.84%
Total	51	

Most of the patients recovered smoothly without a complication (62.74%) but the others (37.26%) had complications after the closure operations shown below (Table.2).

Table 2: Complications Associated with Different Types of Colostomy

Complication (+/-)	Number of patients	Percentage of total sample	Percentage among complications
No complication	32	62.74%	-
SSI	14	27.45%	73.68%
Wound dehiscence	1	1.96%	5.26%
Leak	1	1.96%	5.26%
Seroma	2	3.92%	10.52%
Delayed ileus	1	1.96%	5.26%

Among the patients who developed complications, the surgical site infection (SSI) was the most encountered complication at a rate of (27.45 %) of total sample, accounting for (73.68%) among all the complications followed by Seroma (3.92%) of to-

tal sample while the other complications (1.96%) each of total sample. The age group distribution of complications is shown below (Table.3).

Table 3: Age Group Distribution of Complications.

Age (Yrs.)	Total Cases	No complication		SSI	Dehiscence	Leak	Seroma	Delayed ileus	Total complications	
		for each age group	of total sample						for each age group	of total sample
14-20	3	0	0	1 (1.96%)	0	0	1 (1.96%)	1 (1.96%)	3 (100%)	3 (5.88%)
21-30	15	10 (66.66%)	10 (19.6%)	5 (9.80%)	0	0	0	0	5 (33.33)	5 (9.80%)
31-40	10	7 (70%)	7 (13.72%)	3 (5.88%)	0	0	0	0	3 (30%)	3 (5.88%)
41-50	8	6 (75%)	6 (11.76%)	1 (1.96%)	1 (1.96%)	0	0	0	2 (25%)	2 (3.92%)
51-60	9	6 (66.66%)	6 (11.76%)	2 (3.92%)	0	1 (1.96%)	0	0	3 (33.33%)	3 (5.88%)
61-70	5	2 (40%)	2 (3.92%)	2 (3.92%)	0	0	1 (1.96%)	0	3 (60%)	3 (5.88%)
71-80	1	1 (100%)	1 (1.96%)	0	0	0	0	0	0	0

P-value: 0.264

It is noticed that the complication rate is least encountered in the age group (41-50) years old patients. Although the age group (71-80) shows the best outcomes, it could be due the small sample size for that age group in this study.

The association between the indication of stoma creation and the post-closure complications is shown below (table.4).

Table 4: Indication of Stoma Vs Post-Closure Complication.

Indication of stoma	Total cases	No complication		SSI	Dehiscence	Leak	Seroma	Delayed ileus	Total complication		
		for each indication	of total sample						for each indication	among all complications	of all sample
Penetrating trauma	25 (49.01%)	17 (68%)	17 (33.33%)	6 (11.76%)	1 (1.96%)	0	1 (1.96%)	0	8 (32%)	8 (42.10%)	8 (15.68%)
CA	11 (21.56%)	7 (63.63%)	7 (13.72%)	2 (3.92%)	0	1 (1.96%)	1 (1.96%)	0	4 (36.36%)	4 (21.05%)	4 (7.84%)
Sigmoid volvulus	8 (15.68%)	4 (50%)	4 (7.84%)	3 (5.88%)	0	0	0	1 (1.96%)	4 (50%)	4 (21.05%)	4 (7.84%)
Inflammatory bowel disease	1 (1.96%)	1 (100%)	1 (1.96%)	0	0	0	0	0	0	0	0
Large bowel ischemia	2 (3.92%)	0	0	2 (3.92%)	0	0	0	0	2 (100%)	2 (10.52%)	2 (3.92%)
Distant fistula	1 (1.96%)	1 (100%)	1 (1.96%)	0	0	0	0	0	0	0	0
Fournier gangrene	2 (3.92%)	2 (100%)	2 (3.92%)	0	0	0	0	0	0	0	0
Diverticular disease of the colon	1 (1.96%)	0	0	1 (1.96%)	0	0	0	0	1 (100%)	1 (5.26%)	1 (1.96%)

p-value: 0.353

It is clear that the patients with a history of a diseased colon have higher incidence of complication after stoma closure than patients with non-diseased colonic wall or whose colostomies were made to divert fecal stream away from a distal pathology. The inflammatory bowel disease indication of (0%) of complication could not be explained in this study.

The associations between the types of colostomy and the complications are shown in (Table.5)

Table 5: Number of Each Complication for Each Type of Colostomy.

Type	Total cases	No complication		SSI	Wound dehiscence	Leak	Seroma	Delayed ileus	Total complication		
		for each type	of total sample						for each	among all complications	of all sample
Loop	24	17 (70.83%)	17 (33.33%)	6 (11.76%)	1 (1.96%)	0 (0%)	0 (0%)	0 (0%)	7 (29.16%)	7 (36.84%)	7 (13.72%)
Double barrel	18	11 (61.11%)	11 (21.56%)	4 (7.84%)	0 (0%)	0 (0%)	2 (3.92%)	1 (1.96%)	7 (38.88%)	7 (36.84%)	7 (13.72%)
Hartmann	5	2 (40%)	2 (3.92%)	2 (3.92%)	0 (0%)	1 (1.96%)	0 (0%)	0 (0%)	3 (60%)	3 (15.78%)	3 (5.88%)
Vent colostomy	4	2 (50%)	2 (3.92%)	2 (3.92%)	0 (0%)	0 (0%)	0 (0%)	0 (0%)	2 (50%)	2 (10.52%)	2 (3.92%)

P-value: 0.556

The loop type of colostomy has the least incidence of complications for its type (29.16%) while the vent type of colostomy has the least prevalence of complications among all complications (10.52%) and among the whole sample too (3.92%). The highest incidence of SSI is with loop type (11.76% of all sample, 31.57% among complications).

Also, it is noticed that different sites of colostomies are associated with different percentages of outcomes (Table.6).

Table 6: Association Between Different Sites of Colostomies & Complications.

Type	Total cases	No complication		SSI	Wound dehiscence	Leak	Seroma	Delayed ileus	Total complication		
		for each site	of all sample						for each site	among all complications	of all
Sigmoid colon	17	9 (52.94%)	9 (17.64%)	6 (11.76%)	1 (1.96%)	0 (0%)	1 (1.96%)	0 (0%)	8 (47.05%)	8 (42.10%)	8 (15.68%)
Descending colon	21	13 (61.90%)	13 (25.49%)	5 (9.8%)	0 (0%)	1 (1.96%)	1 (1.96%)	1 (1.96%)	8 (38.09%)	8 (42.10%)	8 (15.68%)
Transverse colon	7	6 (85.71%)	6 (11.76%)	1 (1.96%)	0 (0%)	0 (0%)	0 (0%)	0 (0%)	1 (14.28%)	1 (5.26%)	1 (1.96%)
Ileum	4	2 (50%)	2 (3.92%)	2 (3.92%)	0 (0%)	0 (0%)	0 (0%)	0 (0%)	2 (50%)	2 (10.52%)	2 (3.92%)
(Ileo-transverse anastomosis)	6	4 (66.66%)	4 (7.84%)	2 (3.92%)	0 (0%)	0 (0%)	0 (0%)	0 (0%)	2 (33.33%)	2 (10.52%)	2 (3.92%)

P-value: 0.507

The highest colostomy site related complication rate after stoma closure is with Lt. side colon colostomies (sigmoid colon: 47.05%, descending colon: 38.09%) while the least rate of site related complications after stoma closure was in transverse colon site of colostomy (14.28%).

Discussion

A colostomy is the artificial opening created on the large bowel for the purpose of diverting feces and flatusto exterior where it can be collected in a bag attached to the skin of the anterior abdominal wall [8,9].

Stoma closure is not a complication-free operation, its complications can occur in up to (40%) of cases (37.26% in this study)

and this can be related to some factors, including: The patient's age and the indication for which the colostomy was made; so, it must not be considered as a simple easy operation.

Keeping this in mind, it cannot be expected that all patients with temporary type of colostomies are candidates for its reversal, so a proper patient selection, a proper preparation and a proper timing are cornerstones for successful outcomes [3].

In this matter [10]. did a retrospective analysis on their patients who have a Hartmann's colostomy and analyzed their reversal rate considering the associated patient's parameters [10]. They found that the reversal was possible & successful in (45%) of the patients, younger patients were luckier to get the stoma reversed

successfully. In this study, the age group (41-50) had the best outcomes.

They also found patients with longer periods before closure had better outcomes. The time period in our research was (4-12) weeks. Timing of closure colostomy is still a debate, there are two main opinions: The first opinion is the early reversal to avoid rectal stump atrophy, the second opinion is the delayed reversal after resolution of the inflammatory process in the involved surgical field. Nevertheless, some others believe that it makes no difference neither in the success of the operation, nor in the avoidance of complications [11].

Despite the fact that primary anastomosis has good outcomes but patients in shock state at the time of the initial operation are candidates for stoma creation (regardless the degree of intra-peritoneal contamination) which may explain the high percentage of penetrating injury indication in our sample (49.01%) of all cases.

With regard to the technique used in the anastomosis. shared results showing that a hand sewn anastomosis is a risk factor for leakage which can occur in up to (4%) of cases [12,13]. In this study all patients were hand sewn and the leak occurred in (1.96%) of cases.

Avoiding stoma creation at the site of injury/resection is a good option but when stool diversion is a must, alternative procedures can be used in the acute setting such as primary anastomosis with a proximal loop ileostomy or colostomy. The loop type of colostomy has less risk for complications which goes with this research (70.83% of patients with loop type of colostomy were complication-free), the incidence of wound infection in loop colostomy range is (19.8% - 33.3%) (31.57 % in this study) [15,1-17].

A recent meta-analysis about complications after loop stomas showed that closure of loop ileostomies has even fewer wound infections in comparison to closure of loop colostomies [17-19].

Regarding the site of colostomy, the Lt. side of colon has the best outcome and the transverse colon colostomy has the worst but in this study the results were the opposite which could not be explained (transverse colostomy had 85.71% with no complications which is the highest rate, 14.28% had complications which is the lowest rate) [1].

Conclusion

Closure of a stoma is associated with a variety of complications and should not be considered as a simple operation. Careful patient selection and proper timing for closure are essential points in planning for a stoma closure. The loop type of colostomy is the preferred type. Meticulous surgical technique is very important in achieving a successful outcome.

Recommendations

Colostomies should be avoided whenever possible. Loop colostomies are the preferred type of colostomy as they have less complication. Good patient preparation is necessary for suc-

cessful stoma closure and well-trained surgeon with meticulous technique are needed for better results, using a stapler is better if applicable.

Conflict of Interest: Authors declare no COI

Acknowledgement: All thanks and appreciation to the staff assist in data collection.

Funding: No Funding Sources

References

1. Massenga A, Chibwae A, Nuri AA, Bugimbi M, Munisi YK, et al. (2019) Indications for and complications of intestinal stomas in the children and adults at a tertiary care hospital in a resource-limited setting: a Tanzanian experience. *BMC Gastroenterol* 19: 157.
2. <https://www.healthline.com/health/colostomy#followup>
3. Fonseca alexandre z, uramoto edson, santos-rosa otto m, santin stephanie, ribeiro-jr marcelo (2017) Colostomy closure: risk factors for complications. *Abcd, arq. Bras. Cir. Dig* 30: 231-234.
4. Beck PH, Conklin HB (1975) Closure of colostomy. *Ann Surg* 181: 795-798.
5. Pokorny H, Herkner H, Jakesz R, Herbst F (2005) Mortality and complications after stoma closure. *Arch Surg* 140: 956-960.
6. Merrett ND, Gartell PC (1993) A totally diverting loop colostomy. *Ann R Coll Surg Engl* 75: 272-274.
7. Salih Abdul-kafi Hamooddi, Ahmed Waleed Ibrahim, Qasim Hamza Eriby (2018) Complications of colostomy closure. *Pharma Innovation* 7: 500-502.
8. Steele SR, Maykel JA, Johnson EK (2011) Traumatic injury of the colon and rectum: the evidence vs dogma. *Dis Colon Rectum* 54: 1184-1201.
9. <https://archive.org/details/WilliamsBaileyAndLovesShort-PracticeOfSurgeryNormanWilliamsChristopherBulstrode-PR>
10. Hodgson R, AnV, Stupart DA, Guest GD, Watters DA (2016) Who gets Hartmann's reversed in a regional centre? *Surgeon* 14: 184-189.
11. Fleming FJ, Gillen P (2009) Reversal of Hartmann's procedure following acute diverticulitis: is timing everything? *Int J Colorectal Dis* 24: 1219-1225.
12. Roig JV, Cantos M, Balciscueta Z, Uribe N, Espinosa J, et al. (2011) Sociedad Valenciana de Cirugía Cooperative Group. Hartmann's operation: how often is it reversed and at what cost? A multicentre study. *Colorectal Dis* 13: e396-402.
13. SILVA José Jorge da, SILVA Rafael Melo, COSTA Kárin Kneipp (2015) New alternative for wound protection in laparoscopic colectomy. *ABCD, arq. bras. cir. Dig* 28: 61-64.
14. Yusuf Hakan Çavuşoğlu, Ayşe Karaman, Çağatay Evrim Afşarlar, İbrahim Karaman, Derya Erdoğan, et al. (2015) Ostomy Closures in Children: Variations in Perioperative Care Do Not Change the Outcome. *Indian J Surg* 77: 1131-1136.
15. Blumetti J, Abcarian H (2015) Management of low colorectal anastomotic leak: Preserving the anastomosis. *World J*

Gastrointest Surg 7: 378-383.

16. Geng HZ, Nasier D, Liu B, Gao H, Xu YK (2015) Meta-analysis of elective surgical complications related to de-functioning loop ileostomy compared with loop colostomy after low anterior resection for rectal carcinoma. *Ann R Coll Surg Engl* 97: 494-501.
17. Sier MF, Van Gelder L, Ubbink DT, Bemelman WA, Oostenbroek RJ (2015) Factors affecting timing of closure and non-reversal of temporary ileostomies. *Int J Colorectal Dis* 30: 1185-1192.
18. Daluvoy S, Gonzalez F, Vaziri K, Sabnis A, Brody F (2008) Factors associated with ostomy reversal. *Surg Endosc* 22: 2168-2170.
19. Garber A, Hyman N, Osler T (2014) Complications of Hartmann takedown in a decade of preferred primary anastomosis. *Am J Surg* 207: 60-64.

Copyright: ©2023 Ashraf Abdulrazzaq Mohammed, et al. This is an open-access article distributed under the terms of the Creative Commons Attribution License, which permits unrestricted use, distribution, and reproduction in any medium, provided the original author and source are credited.