

Changing Trends in Ectopic Pregnancy: Its Location and Management

Naiknaware Sachin Vijay

Department of Gyanaec endoscopic surgeon. Parkview Hospital, Mumbai, India.

*Corresponding Author: Naiknaware Sachin Vijay, Gyanaec endoscopic surgeon. Parkview Hospital, Mumbai, India.

Submitted: 09 Oct2023

Accepted: 19 Oct 2023

Published: 23 Oct 2023

Citation: Naiknaware Sachin Vijay (2023). Changing Trends in Ectopic Pregnancy: Its Location and Management. Naiknaware Sachin Vijay Gyanaec Endoscopic Surgeon. J of Clin Case Stu, Reviews & Reports 2(1).01-05.

Abstract

Ectopic pregnancy is defined as implantation of fertilised ovum outside uterine cavity. recently there has been an increase in incidence of ectopic pregnancy & many uncommon locations are diagnosed more frequently than before; in this article we will be having look at different sites of ectopic pregnancy.

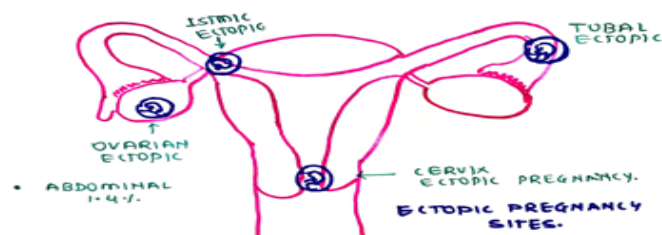
Conclusion

With at the advancement in imaging & of laparoscopy there is greater horizon of opportunity opened for diagnosing and simultaneously treating some of the dread complications those are attributed to ectopic pregnancy, keeping in mind the differential of different kind of ectopic gestation will surely help to diagnose and treat the condition before is get complicated.

Introduction

Ectopic pregnancy is defined as implantation of fertilised ovum outside uterine cavity. recently there has been an increase in incidence of ectopic pregnancy, may be related to increased number of IVF procedures and ovulation induction, increased province of sexually transmitted disease, tubal sterilisation procedures and re-canalisation. on, delayed childbearing and higher rates of clinical detection due improvised technologies. women with a history of ectopic pregnancy have approximately eight fold greater risk of experiencing another ectopic pregnancy [1,2].

Most common site of ectopic pregnancy is in fallopian tube with ampullar portion harbouring 80% of tubal pregnancies.



Other Locations of Ectopic Pregnancies Are.

- Cervix-0.2 %
- Abdomen -1.4%
- Ovary-0.2%
- Cesarean scar site ectopic pregnancy
- Heterotypic ectopic pregnancy
- Interstitial / cornual ectopic pregnancy
- Abdominal ectopic pregnancy.

Common presenting symptoms of ectopic pregnancy are amenorrhoea, lower abdominal pain and vaginal bleeding. predisposing factors are pelvic inflammatory disease, adhesions due to previous abdominal or pelvic surgery, sexually transmitted diseases, endometriosis, intrauterine contraceptive devises, history of previous ectopic pregnancies, previous miscarriages and use of in vitro fertilisation techniques.

The general complications that can occur are severe lower abdominal pain, intra-tubal bleeding followed by hepatoma, intra-peritoneal bleeding, and sometimes hemorrhagic shock, and in few undiagnosed cases even maternal death can occur in about 13% of patients.

Ectopic pregnancy is diagnosed based on clinical history of amenorrhea patients symptoms of severe pain and vaginal spotting and bleeding with either positive pregnancy test or positive BHCG value. clinical examination reveals some kind of adnexal mass with varying degrees go cervix motion tenderness. and it can be confirmed with either trans abdominal and trans-

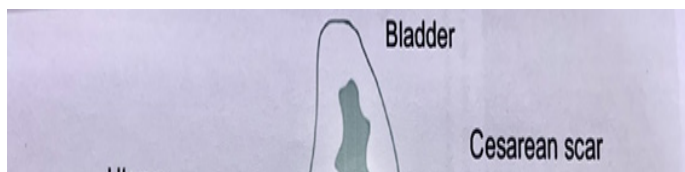
vaginal sonography also doubling 31time of BHCG is to be monitored if there I less than 66% increase in BHCG value in 24-48 hrs ectopic pregnancy can be suspected and these patients need careful monitoring.

Also, serum progesterone level <12 ng/ml goes in favour of ectopic pregnancy or miscarriage. Recently alongside tubal ectopic pregnancy more other sites are detected more frequently due to increased use of ovulation induction, in vitro fertilisation techniques and improved imaging equipments and better understanding of disease process. Now we will discuss other sites of ectopic than tubal pregnancy.

Cesarian Scar Ectopic Pregnancy

It is rare location of ectopic pregnancy occurring in approximately 1 in 200 pregnancies and now its incidence is rising in parallel with increase in primary and repeat cesarian section [3].

Globally the caesarian section rates average 18.6% of all births, predisposing factors for cesarian scar ectopic



Pregnancy is cesarian section, myomectomy, uterine evacuation, previous abnormally adherent placenta, manual removal of placenta metroplasty, hysteroscopy and in vitro fertilization [4].

There are two types of cesarian scar ectopic, TYPE 1: - caused by Implantation of embryo in prior scar with progression towards crevice isthmic space and uterine cavity. TYPE 2: - is caused by deep implantation of embryo into scar defect with growth into myometrium and uterine surface which may result into uterine rupture and massive haemorrhage in first trimester of pregnancy. Many a times it does not have any specific symptoms and patient may present with severe bleeding during pregnancy or at the time of curettage, uterine rupture, disseminated intravascular coagulation or even death. undiagnosed scar ectopic can also present with heavy bleeding hemo- peritonium and shock after termination of early pregnancy or missed abortion [5].

Diagnosis of scar ectopic depends upon history of previous cesarian section, typical symptoms attributed to ectopic pregnancy, positive urine or BHCG tests and typical findings on ultrasonography. transvaginal USG can diagnose scar ectopic with a sensitivity of 84.6%. diagnostic criteria for scar ectopic by transvaginal sonography.

- An empty uterine and cervical canal.
- Gestation sac located at the anterior wall of the isthmic portion separated from endometrial cavity or fallopian tube in a previous scar.
- A gestation sac embedded within the myometrium and fibrous tissue of caesarian section scar at the lower uterine segment with absence of defect in myometrium between the bladder and gestation sac.
- High velocity low impedance vascular flow surrounding the gestation sac.

Once the diagnosis is confirmed the management option for the treatment of scar ectopic depends on various factors as gestational age, hemodynamic stability of patient.

Serial follow up options and availability of expert surgeon, the aim of management is to prevent the massive haemorrhage, conserve the uterus for further fertility and maintain the quality of life of a patient.

Medical management options include systemic methotrexate, local methotrexate, and other embryocide and combinations of both. Methotrexate therapy is considered when gestation sac is not more than 8 weeks without cardiac activity. It is been reported that when BHCG value is less than 5000 miu/ml and myometrial invasion thickness was less than 2mm then systemic methotrexate has a success rate of 71 to 80 %.

Local administration of methotrexate is also found beneficial. trans abdominal or transvaginal ultrasound guided methotrexate is injected in scar ectopic. local injection in gestation sac of potassium chloride, hyper- osmolar glucose , etoposide and trichlorosanthine has been reported beneficial in scar ectopic management.

As medical management can interrupt the pregnancy, bleeding may continue for longer time, hence medical management is combined with surgical aspiration of products under ultrasound guidance. this may preserve the fertility but require strict BHCG follow up which may take 4 to 16 week to drop to non-pregnant level.

In case of intractable haemorrhage due to scar ectopic pregnancy, the homeostatic measures that can be tried are ballon tamponade by foleys catheter, local vasopressin injection, prior selective uterine artery embolisation and bilateral uterine artery ligat

Hysteroscopic evacuation of products of conceptions also can be done. It gives a chance of direct visualisation of scar defect, removal of products of conception under vision and coagulation of bleeding vessels at implantation site to control the haemorrhage.

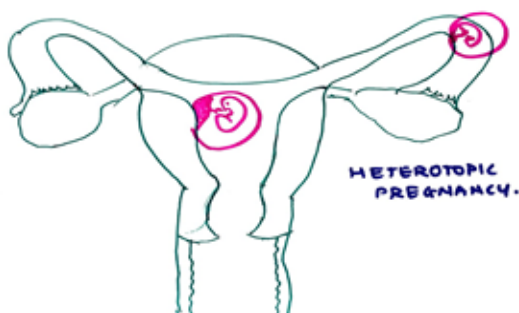
Exploratory laparotomy with surgical evacuation of products of conception and freshening of scar edges and suturing back to preserve the scar integrity is done. First laparoscopic resection of scar ectopic pregnancy was done [6].

Principles to be followed during laparoscopic surgery for scar ectopic are: minimise bleeding by local injection of diluted vasopressin, coagulation of bleeding sites by bipolar, removal of scar tissue and closure of defect by endoscopic suturing.

As scar ectopic pregnancy is complex disorder with many complications' accurate early diagnosis and effective management are key to reduce maternal morbidity and mortality.

Heterotopic Pregnancy

The coexistence of intrauterine and ectopic pregnancy is called as heterotopic pregnancy, it was first reported in 1708 as an autopsy finding. In natural conception cycle it is a rare event occurring in <1 in 30000 pregnancies, about 0.08% of all pregnancies but in pregnancies with assisted reproductive techniques this incidence increased to 1 in 100 to 1 in 500 pregnancies and occurs in 5% of pregnancies achieved after IVF. Along with normal intrauterine pregnancy most common site for ectopic pregnancy is fallopian tube followed by cornua, other rare sites are cervix, ovary, and abdomen.



Most patients are asymptomatic (24%) others can present with lower abdominal pain (72%) & vaginal bleeding in (54%) of patients. Heterotopic pregnancy is associated with one of following risk factors [7].

- Tubal pathologies, tubal surgeries, infection, previous ectopic pregnancy.
- Use of ovulation induction drugs.
- Ovarian factors.
- Zygote abnormalities.
- Endometriosis.
- Unilateral salpingectomy.
- Uterine contractions caused by embryo transfer catheter during IVF procedures or direct insertion of embryo into fallopian tube can cause heterotopic pregnancy.

Diagnosing a heterotopic pregnancy, a challenge because of simultaneous intrauterine gestation sac raised BHCG and similar symptoms of patients therefore it is recommended to do high resolution ultrasonography with close monitoring of adnexa at 4 to 6 weeks of gestation after embryo transfer for the possible early diagnosis of heterotopic pregnancy & to prevent its untoward complications.

Treatment of heterotopic pregnancy depends upon site of ectopic, presentation and severity of symptoms, and expertise of treating surgeon. In today's time laparoscopic salpingectomy or salpingostomy is the treatment of choice because of better outcome for intrauterine pregnancy.

Interstitial / Cornual Pregnancy

The term cornual/ angular/ interstitial pregnancy is often used interchangeably to define the pregnancy that is implanted in the interstitial portion of fallopian tube which is defined as the tubal segment traversing the muscular wall of uterus. Interstitial pregnancy accounts for 1.6% of all ectopic pregnancies and 2- 4% of tubal gestation [8].

Its incidence increased from 1.9% to 7.3% due to use of artificial reproductive technologies also it is associated or common in patients who had ipsilateral salpingectomy, pelvic inflammatory disease, salpingitis isthmica nodosa, previous uterine surgery and uterine anomalies.

High index of suspicion with clinical history and BHCG level along with transvaginal ultrasound helps to arrive at accurate diagnosis of interstitial or cornual pregnancy. It is managed either by conservative methods using systemic methotrexate or USG guided local administration in Gsac. Surgical methods used for managing cornual pregnancy are cornual wedge resection, cornuostomy, mini cornual excision, placing a Vicryl loop around the uterine cornua, and salpingectomy by laparoscopy are re-

ported techniques in literatures for cornual pregnancy management [9].

Due to risk of uterine rupture after an interstitial pregnancy any subsequent pregnancy should be monitored carefully and elective cesarian section should be done to avoid the risk of uterine rupture. even there are some cases of ectopic pregnancy reported after bilateral salpingectomy and pregnancy by IVF.

Ovarian Ectopic Pregnancy

Incidence of ovarian ectopic pregnancy in natural conception range from 1 in 2000 to 1 in 6000 deliveries accounting for 3% of all ectopic pregnancies. Ovarian ectopic pregnancy appears to be due to reflux of fertilised ovum to ovary, other hypothesis for ovarian ectopic are release of ovum from ruptured follicle, malfunction of the tubes, & inflammatory thickening of tunica albuginea & use of intrauterine contraceptive devices.

Spigelberg's criteria is used for intraoperative diagnosis of ovarian ectopic: includes intact fallopian tube on affected side, fetal sac must occupy the position of the ovary on affected side, ovary connected to uterus by ovarian ligament, ovarian tissue must be present in sac wall which is confirmed by histopathology [10].

With the improvements in imaging technologies & expertise ovarian pregnancies are diagnosed more frequently than before and also before rupture. USG showed double echogenic rings within a hypo echoic lateral uterine mass.

Laparoscopy with a conservative treatment is the cornerstone of management including options as ovarian wedge resection, ovarian pregnancy enucleation, corpus lute cystectomy, trophoblast curettage with coagulation or suturing the bed of ovarian pregnancy, & sometimes oophorectomy needed.

Abdominal Pregnancy

It is defined as pregnancy in peritoneal cavity exclusive of tubal, ovarian or inter-ligamental locations. It can be primarily located in peritoneal cavity or secondary to ruptured ectopic pregnancy or tubal abortion.

Pouch of Douglas is the most common location for abdominal pregnancy followed by meso-salpinx and omentum. It represents about 1 to 1.5% of all ectopic pregnancies with an estimated incidence of 1 in 8000 to 1 in 10000 pregnancies. it is a severe life-threatening condition due to risk of massive

haemorrhage from partially separated placenta at any stage of pregnancy.

For diagnosing abdominal pregnancy Studdiford's criteria needs to be fulfilled which includes normal bilateral fallopian tubes & ovaries, absence of utero-peritoneal fistula, pregnancy related exclusively to peritoneal surface & early enough to eliminate the possibility of secondary implantation following a primary location fallopian tube.

Secondary abdominal pregnancy originates in fallopian tubes and less commonly in ovaries & reimplants in the peritoneum where the embryo or foetus continue to grow. clinically abdominal pregnancy presents as severe lower abdominal pain which is a most consistent finding. It is diagnosed by clinical history, symptoms and sonography. Also, laparoscopy is an invaluable tool in diagnosing and simultaneously treating the abdominal pregnancy where other imaging modalities are in doubt [11].

Nowadays due to advancements in diagnostic imaging modalities, frequent use of in vitro fertilisation techniques, late marriages, increased incidence of sexually transmitted diseases and increased incidence of cesarian sections worldwide many uncommon locations of ectopic pregnancies are coming to light and diagnosed with more accuracy before getting complicated, so is thing with management ,with at the advent of laparoscopy there is greater horizon of opportunity opened for diagnosing and simultaneously treating some of the dread complications those are attributed to ectopic pregnancy, keeping in mind the differential of different kind of ectopic gestation will surely help to diagnose and treat the condition before is get complicated.

Reference

1. Takeda A, Manabe S, Mitsui T, Nakamura H (2006) spontaneous ectopic pregnancy occurring in the isthmic portion of remnant of tube after ipsilateral salpingectomy. Report of 2 cases. J Obstet Gynecol. Res 32: 190-194.
2. Bongsagard N, Lund C, Ottensen B, Nilas L (2003) improved fertility following conservative surgical treatment of ectopic pregnancy. Int J Obstet Gynecol 110: 765-770.
3. Diagnosis and management of ectopic pregnancy (2006) Green top guidelines no-21. BJOG 123: e15-55.
4. Patel MA (2015) Scar ectopic pregnancy. J Obstet Gynecol 65: 372-375.
5. Ilan E Timor-Tritsch, Ana Monteagudo, Rosalba Santos,

-
- Tanya Tsymbal, Grace Pineda, et al. (20102) The diagnosis, treatment and follow up of cesarian scar pregnancy. AM J Obstet Gynecol 207: 44-46.
6. C L Lee, C J Wang, A Chao, C F Yen, Y K Soong (1999) Laparoscopic management of an ectopic pregnancy in a previous cesarian section scar. Hum REPROD 14: 1234-1236.
 7. D Peleg, I Bar-Hava, M Neuman-Levin, J Ashkenazi, Z Ben-Rafael (1994) Early diagnosis and successful non-surgical treatment of viable combined intrauterine and cervical pregnancy. Fertil Steril 62: 405-408.
 8. Iau S, Tulandi T (1999) Conservative medical & surgical management of ectopic pregnancy. Fertile Steril. 72: 207-215.
 9. Ng S, Hamontri S Chua I, Chern B, Siow A (2009) Laparoscopic management of 53 cases of cornual ectopic pregnancy. Fertile Steril 92: 448-452.
 10. Spigelberg O (1878) Causistik ovarialschwangerschaft. Arch Gynecol 13: 73.
 11. Daniel Nkusu Nunyalulendho, Ellen M Einterz (2008) Advanced abdominal pregnancy: case report & review of 163 cases reported since 1946. Rural Remote health 8: 1087.

Copyright: ©2023 Sachin Vijay This is an open-access article distributed under the terms of the Creative Commons Attribution License, which permits unrestricted use, distribution, and reproduction in any medium, provided the original author and source are credited.